

Electrocardiogram (EKG/ECG) PROTOCOL

About EKGs

An EKG records the electrical conductivity of the heart and is used in the investigation of heart disease. An EKG reading can determine whether heart rate and rhythm are normal and can determine the size and position of the chambers, any damage to the heart, and effects of drugs or devices to regulate the heart. Electrocardiography serves as the gold standard for the noninvasive diagnosis of arrhythmias (irregular heart beats) and conduction disturbances.

When an EKG is done, several electrodes are attached to the arms, legs and chest to measure the electrical activity from different locations. In clinical practice, the 12-lead EKG is most commonly used. Information from the electrodes is combined in different ways to obtain 12 “leads” which measure the electrical activity of the heart from 12 different directions. The 12-lead EKG places 6 electrodes on the chest (Precordial Leads) and 4 electrodes on the arms and legs (Standard Leads and Augmented Limb Leads). EKGs represent a safe, readily available, and inexpensive technology for assessing patients at risk of heart disease. For more information and illustrations, see “About EKG Leads” on pages 3 and 4.

Importance of Proper Procedure

A number of factors may alter the quality of recorded EKGs. Some of these are patient-related (patient movement, jitters, etc.) and some are operator-related. Operators should ensure that chest (Precordial) electrodes are placed in the proper position and that they make good skin contact to minimize errors. Incorrect placement of chest and/or limb electrodes can cause alterations in EKG readings, including a false diagnosis of infarction (heart attack).

Why Are We Doing EKGs in our Studies?

We are finding that people with HIV infection, especially if on HAART (highly active anti-retroviral therapy), may be at increased risk of developing elevated cholesterol and lipids, insulin resistance and diabetes, and hypertension. All of these conditions increase risk of heart disease. EKGs represent a safe, readily available, and inexpensive technology for assessing patients at risk of heart disease.

EKG Protocol, continued

Procedure (using Hewlett Packard M1705A)

- Lie participant on bed.
- Rub lead spots with alcohol (to remove lotion, creams, perspiration, etc).
- Place 6 tabs in the following order across chest (**Precordial leads**). Start by counting 4 ribs down.
 - V1 - 4th intercostal space, right side of sternum
 - V2 - 4th intercostal space, left side of sternum
 - V4 - lined up below nipple
 - V3 - lined up half-way between V2 and V4
 - V5 - to the right of V4 on a straight line not curved up
 - V6 - next to V5 on a straight line not curved up toward arm pit (not to be directly under arm pit).
- Place 1 tab on each arm and leg with tab facing outwards (**for Augmented Limb and/or Standard leads**). DO NOT PLACE ON BONE. The right clip is the ground.
- Attach alligator clips with color facing up
- See Illustrations on pages 3 and 4 for information on Precordial and Augmented Limb leads.

Press "Standby/On"

- Press ID - for Patient ID#----INSERT 7 DIGIT MEDICAL RECORD #, then ENTER (5)
- For "name" INSERT PT INITIALS AND ID # (IE. c1m133), then ENTER
- for "age" INSERT AGE, then ENTER
- for "sex" PRESS F2 to choose male/female, then ENTER
- for "operator" INSERT STAFF INITIALS, then ENTER
- for "Department" , "physician", "chest pain" etc. ENTER out of it

To start test PRESS GREEN AUTO button

- "Acquiring EKG" appears on the display followed immediately by --
- "Analyzing EKG" appears on the display

NOTE: If EKG is of bad quality, (can't see P, QRS, and T wave pattern or getting "artifact" message)

PRESS STOP to avoid saving to the disk - allow about 1 minute to do this - and check the following:

- Placement of tabs - try placing limb tabs above elbow and above knee to get a fatter area
- Be sure the tab is between the blue plastic clip and the metal - clip needs to be replaced if the metal part is separating from the lower portion of the clip
- Check the base where the leads are coming out of to be sure they're not loose
- Be sure the tabs are not too dry

EKG will now print out in a usual manner

- EKG will store information onto the disk (BE SURE NOT TO MOVE MACHINE WHILE DISK LIGHT IS ON. WAIT UNTIL DISK LIGHT TURNS OFF BEFORE TURNING OFF MACHINE)

PRESS F1 to end test and then PRESS STANDBY/ON button to turn off

- Write visit on printout and place in red bin in NFHL office for physician to read

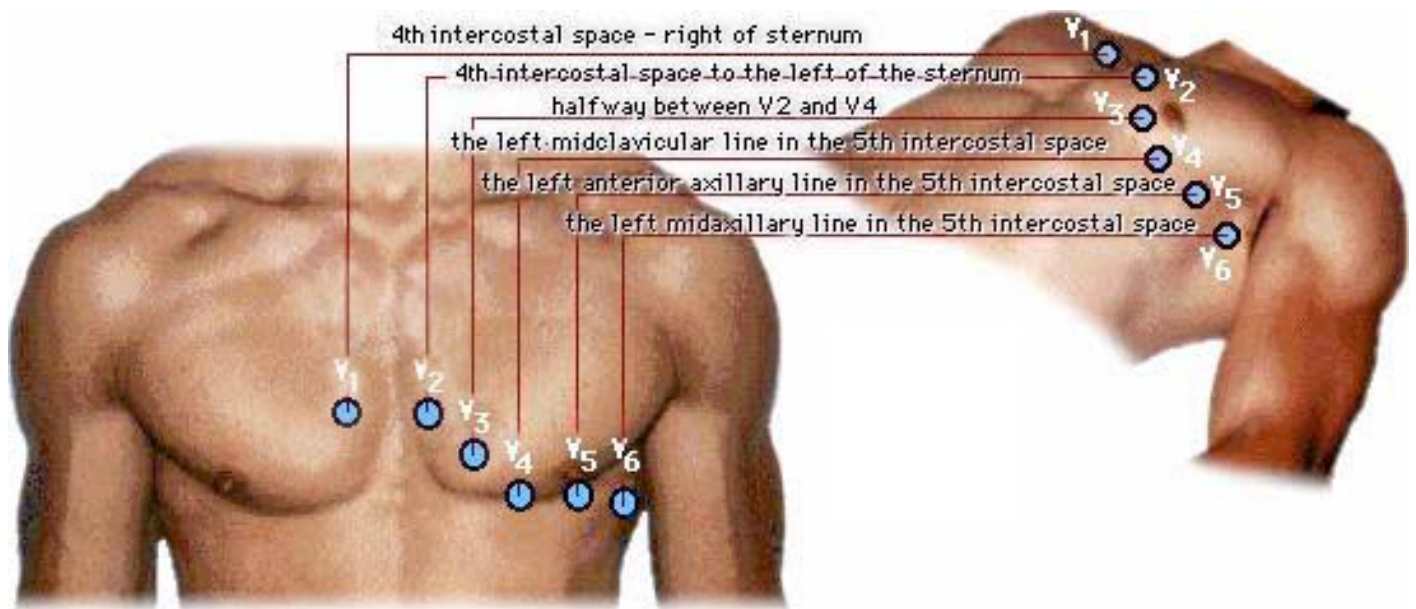
EKG Protocol, continued

About EKG Leads

EKG Precordial (Chest) Leads

These six unipolar leads, each in a different position on the chest, record the electric potential changes in the heart in a cross sectional plane. Each lead records the electrical variations that occur directly under the electrode. They are “unipolar” in that they measure the electric potential at one point

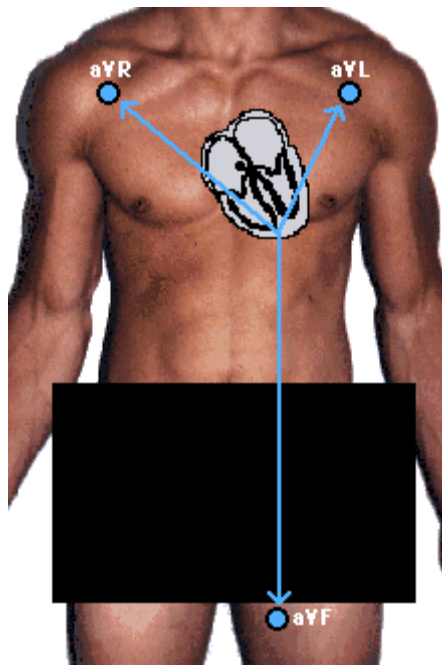
with respect to a null point (one that does not register any significant variation in electric potential during contraction of the heart).



EKG Protocol

About EKG Leads, continued

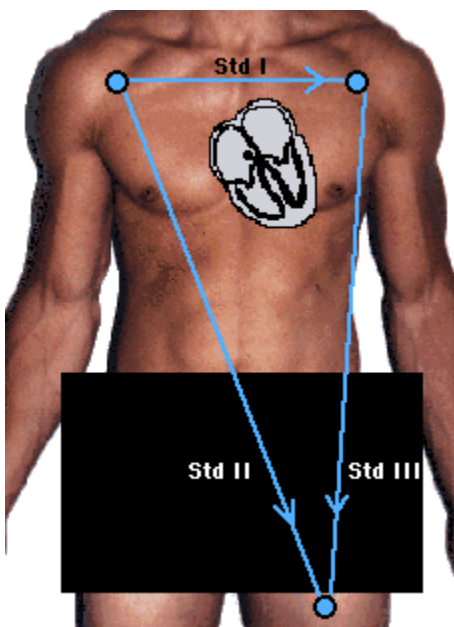
EKG Augmented Limb Leads



Placing one tab on each arm and leg, results in three unipolar leads, called the “augmented limb leads.”

These three leads are referred to as **aVR** (right arm), **aVL** (left arm) and **aVF** (left leg). They record a change in electric potential in the frontal plane. Although the electrodes are placed on each arm and leg, they measure the electrical activity between the heart and shoulders and heart and groin.

EKG Standard Leads



The same three leads that form the augmented limb leads also form the standard leads, usually designated as I, II, and III. They are all bipolar (they detect a change in electric potential between 2 points) and detect an electrical potential change in the frontal plane.

Lead I is between the right arm and left electrodes, the left arm being positive.
 Lead II is between the right arm and left leg electrodes, the left leg being positive.
 Lead III is between the left arm and left leg electrodes, the left leg again being positive.